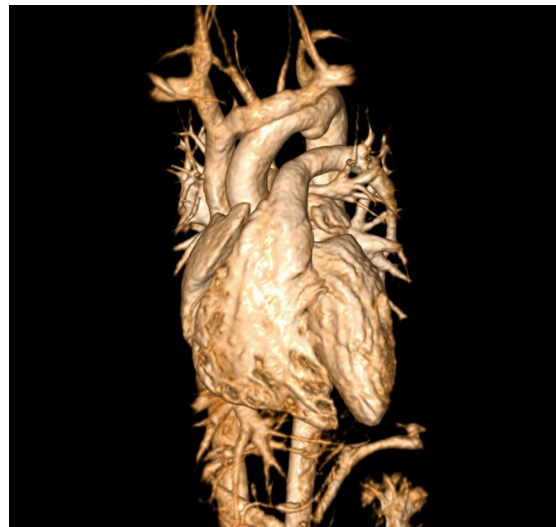


Cardiovascular Imaging Core (CIRC)

The Cardiovascular Imaging Core (CIRC) opened in January 2011 at Children's Healthcare of Atlanta, Egleston Campus. The CIRC core lab provides high quality, non-invasive cardiac imaging support for investigators involved in clinical research involving infants, children and adolescents in a dedicated research setting. Dedicated staff have experience transcending innovation by developing and utilizing imaging modalities and techniques not typically seen in the clinical arena for clinical and basic research. CIRC's dedicated laboratory space is located in the Children's Healthcare of Atlanta, Egleston and Scottish Rite campuses.



Team Members

Ritu Sachdeva, MD, FACC, FASE
Medical Director

Joan Lipinski, MS, RDCS, RDMS
Manager of Echocardiography & CIRC

Nicole Krupa, MPH
Research Coordinator
Nicole.Krupa@choa.org

Kelsey Zinck, MPH
Research Coordinator
Kelsey.Zinck@choa.org

Sassan Hashemi, MD
Imaging Scientist

Research Sonographers

David Cox, RDCS

Falon McGaughy, RDCS

Gemma Morrow, RDCS

Brian Schlosser, BS, RDCS, RDMS, FASE

How to Access the CIRC

The main CIRC lab is located at
Children's Healthcare of Atlanta
at Egleston in

Outpatient Cardiac Services
2nd Floor of Tower 1

Phone: (404) 785-CIRC (2472)

[http://www.pedsresearch.org/cores/
detail/cardiovascular-imaging-research
-core-circ](http://www.pedsresearch.org/cores/detail/cardiovascular-imaging-research-core-circ)

Meet the New Staff



Kelsey Zinck, MPH
Research Coordinator

Kelsey received her Bachelor of Arts degree in Communication Studies with a health concentration from The College of New Jersey and her Master of Public Health in Community Oriented Primary Care at The George Washington University. Before CHOA, she was a Research Coordinator in multiple myeloma at the Winship Cancer Institute at Emory. Kelsey has also spent time volunteering on community-based projects to improve outcomes for low-income populations and youth. She also completed two international public health trips to Durban, South Africa and Lima, Peru.

Our Services

Echocardiograms

- Transthoracic Echocardiography
 - 2-dimensional (2-D) echocardiography
 - Color and spectral Doppler echocardiography
 - M-Mode echocardiography
 - Tissue Doppler Velocity Imaging
 - Real-time 3-D Imaging
 - Strain and Strain rate imaging
- Transesophageal Echocardiography
- Fetal Echocardiography
- Stress Echocardiogram

Exercise stress testing

Electrocardiograms

Vascular function assessment:

- Carotid intimal medial thickness (cIMT)
- Brachial flow mediated dilation (FMD)
- Applanation tonometry

Cardiac magnetic resonance imaging (cMRI)

- Cardiac function quantification
- Phase-contrast velocity mapping
- Coronary imaging
- Scar imaging and quantification
- Cycle Ergometer exercise MRI
- Strain analysis (feature tracking)
- 4-dimensional flow analysis

Data Core site capabilities

- Data storage
- Data management
- Data analysis

Consultative expertise for protocol development

Post-processing of previously acquired images

- DVD burning
- Shipping DVDs with images

Echocardiographic Image Processing

- David Cox, RDCS

TomTec is an imaging and information management software that allows CIRC lab to perform a comprehensive array of automated measurements. We use this software to perform offline measurements, such as left ventricular volumes and ejection fraction using Simpson's biplane method, strain and strain rate analysis, and tissue Doppler quantification. Tomtec gives us the capability to make these measurements on images from multiple vendors.

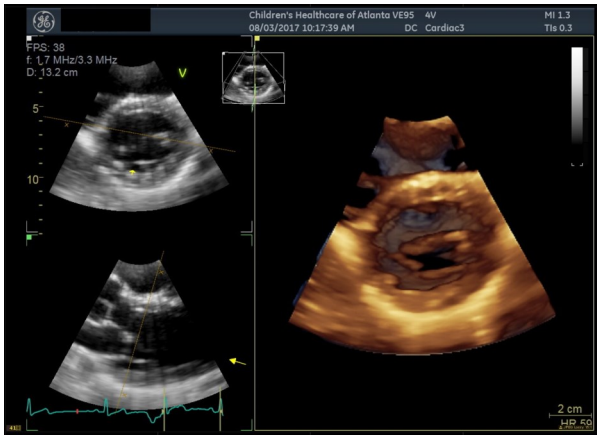


Figure 1. 3-dimensional imaging of mitral valve

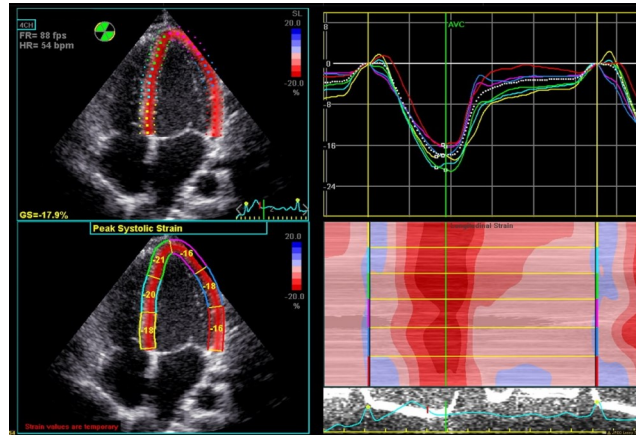


Figure 2. Strain analysis of left ventricle

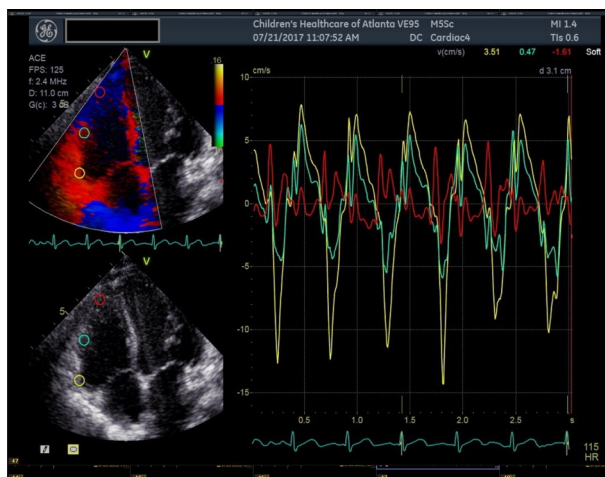


Figure 3. Tissue Doppler imaging of right ventricle

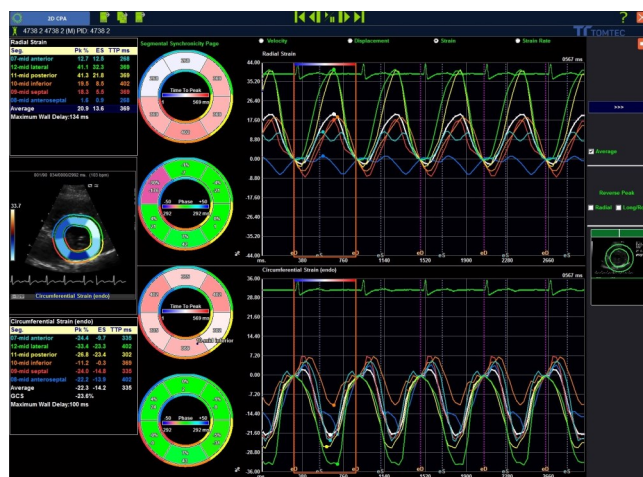


Figure 4. Global circumferential strain of left ventricle

Figure 1. Advancements in 3-D imaging allow for greater real-time analysis of heart chambers and structures, such as the mitral valve shown here.

Figure 2. Automated speckle-tracking is an emerging technique for detecting and quantifying subtle disturbances in LV systolic function, such as predicting ventricular dysfunction secondary to chemotherapy exposure *before* a reduction in ejection fraction occurs.

Figure 3. Tissue Doppler imaging (TDI) is used to measure the velocity of the myocardium throughout the cardiac cycle. This image shows TDI-derived velocities across three different areas of the right ventricular free wall.

Figure 4. Post-processing assessment of the global circumferential strain rate of left ventricle.

Recent Presentations

Our team is committed to research and has had the opportunity to contribute to medical science through abstract presentations and publications. Below is a list of selected abstracts presented within the last year at various national and regional meetings through research supported by CIRC .

American Society of Echocardiography

Revisiting the Bernoulli Equation in Coarctation Following Norwood Procedure. Sassan Hashemi MD, Christopher J. Petit MD, Ritu Sachdeva MBBS. **2017 ASE Foundation Top 25 abstracts**

Appropriateness of Outpatient Transthoracic Echocardiogram Orders Following Cessation of an Active Educational Intervention. Shae Anderson MD, Courtney E. McCracken PhD, Ritu Sachdeva MBBS. **2017 ASE Foundation Top 25 abstracts**

The Clinical Utility of Exercise Stress Echocardiography: How Does it Impact Clinical Decision Making in Pediatric Patients? Heather Friedman MPH, Nicole Allen MPH, Megan Stark MS, Ritu Sachdeva MBBS, William L. Border MBChB, MPH

Tricuspid Annular Plane Systolic Excursion as a Marker of Right Ventricular Dysfunction in Pediatric Patients with Dilated Cardiomyopathy. Ericka S. McLaughlin DO, Curtis Travers MPH, Senthil Ramamurthy MS, William L. Border MBChB, MPH, Shriprasad Deshpande MBBS, MS, Ritu Sachdeva MBBS

Does *High* Pulmonary Venous Forward-Reverse VTI Ratio Predict Postnatal Morbidity Related to Pulmonary Over-Circulation in the Fetus with Hypoplastic Left Heart Syndrome? Jessica Posey MSN, FNP-C, Janet Figueroa MPH, Courtney E. McCracken PhD, Falon McGaughy RDCS, Kristina Lindsey RN, Heather Friedman MPH, Nicole Allen MPH, Ritu Sachdeva MBBS, Erik Michelfelder MD

Longitudinal Assessment of Quantitative Measures of Right Ventricular Function in Hypoplastic Left Heart Syndrome. Ololade Akintoye MD, Curtis Travers MPH, William L. Border MBChB, MPH, Erik Michelfelder MD, Ritu Sachdeva MBBS

Rate of Decline in Ejection Fraction may Predict the Development of Systolic Dysfunction in Childhood Cancer Survivors. Kirsten Rose -Felker MD, Michael S. Kelleman MSPH, Rebecca W. Lewis MPH, Lillian R. Meacham MD, Karen E. Effinger MD, Ritu Sachdeva MBBS, William L. Border MBChB, MPH

American College of Cardiology

Is Tricuspid Annular Plane Systolic Excursion (TAPSE) a Reliable Marker of Right Ventricular Function in Hypoplastic Left Heart Syndrome? Ololade O. Akintoye MD, Curtis Travers MPH, William L. Border MBChB, MPH, Christopher J. Petit MD, Erik Michelfelder MD, Ritu Sachdeva MBBS

American Pediatric Surgical Association

Improvements in Vascular Health in Obese Adolescents After Surgical Weight Loss. Andrew D. Morris MD, Luke Timmins PhD, Kim Rooney BS, Charles Searle MD, Aimee Block B, Ritu Sachdeva MBBS, Stephanie Walsh MD, Luke Brewster MD PhD, Mark Wulkan MD

Southeastern Pediatric Research Innovation Conference

Background Phase Correction in Congenital Heart Disease: Does Reliability Vary Based on Underlying Disease Type? Sassan Hashemi MD, Senthil Ramamurthy MS, W. James Parks MD, Denver Sallee III MD, Timothy C. Slesnick MD

Exercise Clearance for Young Athletes: Is Exercise Stress Echocardiography a Useful Tool? Nicole Allen MPH, Heather Friedman MPH, Megan Stark MS, Ritu Sachdeva MBBS, William L. Border MBChB, MPH

Using Serial Exercise Testing to Guide Treatment of Pediatric Patients with Tetralogy of Fallot. Megan Stark MS, Heather Friedman MPH, Peter Fischbach MD

Virtual Transcatheter Pulmonary Valve Replacement to Optimize Patient Outcomes in Pediatric Patients. Sassan Hashemi MD, W. James Parks MD, Denver Sallee III MD, Holly D. Bauser-Heaton MD, Dennis W. Kim MD, Christopher J. Petit MD, Robert N. Vincent MD, Timothy C. Slesnick MD

Newsletter Contest

Thank you for reading our newsletter!

If you are able to correctly answer the 3 questions below, email the answers to Nicole.Krupa@choa.org with the subject line, **CIRC Newsletter Contest** by **8/31** to be entered in our prize drawing! Please include your name, email address and number with your email submission.

Hint Answers can be found in the newsletter.

1. In what year was CIRC started?

2. CIRC has the ability to perform vascular function assessment in pediatric patients

-True

- False

3. CIRC can facilitate post-processing of echocardiographic images using a vendor-neutral platform

- True

- False